

Fluorescent Microscopy of Gastric Mucosal Tissue of Cattle and Pigs

Nitovski A^{1*}, Bisa Radović¹, Dragana Grčak¹, Valentina Milanović¹,
Milena Potić², Milenković M¹, Grčak M¹.

¹Faculty of Agriculture, Lešak, University of Kosovska Mitrovica, Kosovo and Metohy, Serbia.

²Faculty of Medicine, Nis, Serbia

*Corresponding Author's Email: anitovski@gmail.com

Abstract – The gastrointestinal tract of cattle and pigs represent the digestive organs are two different kinds of animals. Cattle are herbivores and have a complex stomach multi-chamber, which consists of a reticulum, rumen, omasus and the true stomach-abomasus. Pigs are omnivores and have single-chamber stomach. Using modern methods of histological analysis, such as fluorescence microscopy, we have done histological slides of 15 samples of pig stomachs and true stomach (abomasus) cattle. In the analysis of histological material we used fluorescence microscopy. The analysis we noticed all the cell types that characterize the area of the cardia, fundus and pylorus. We have shown the cells of the stomach of cattle and pigs obtained by fluorescence microscopy. On obtained recordings are observed all elements of gastric glands situated in foveols gastric fundus, whose area was in particular observed in the our work.

Keywords – Cattle, Pigs, Stomach, Cells, Glands, Fluorescent Microscopy.

I. INTRODUCTION

Following the scientific literature (books, monographs, papers) in the last half century, we noticed that there was an evolution of knowledge about the anatomical, histological and physiological characteristics of the gastric mucosa. We observed that the introduction of technologically more sophisticated methods to test always led to a shift in the evolution of these findings. Great progress in understanding the macroscopic and microscopic structure of the gastric mucosa has been made with the introduction of the electron microscope in histological examination of cells and tissues. In the past, each decade has followed the introduction of new biophysical and biochemical methods in the study of histological structure and function of the gastric mucosa, which contributed to the literature and, in each decade occurrence new knowledge in this field. As standards in analyzing anatomical, histological and physiological characteristics of the gastric mucosa we took the information that we get from the best books, whose authors are eminent professors in these fields. In addition to these data, we used the results of the papers that have studied anatomy, histology and physiology of gastric mucosal tissue of humans and domestic animals. Since monitoring of complete anatomical, histological and physiological characteristics of the gastric mucosa falls within the ambit of the wider scientific and research work, we decided to next anatomical, histological appearance of complete mucosal surface of the stomach, the maximum

consideration to the observation of gastric glands situated in the area of the fundus of the stomach.

Newer diagnostic tools, instruments and apparatus ensured that at the cellular level can detect and diagnose changes which greatly facilitated the establishment of the correct diagnosis and appropriate therapy. Of these modern methods pointed to gastroscopy, newer methods Histological particularly fluorescence microscopy, immunohistochemical, fluorescent situ hybridization (FISH) on paraffin sections and other methods that are applied depending on the level of health care and laboratory equipment. At the tertiary level of health service delivery, in Institute and Clinics, and lab equipment at a much higher level, and the greater the variety of diagnostic methods in qualitative and quantitative terms (Nitovski A, 2015).

II. LITERATURE SURVEY

The literature review we chose to name as a reference, eminent authors from this area at regular intervals. In addition to anatomical, histological and physiological characteristics of the stomach, we monitored and diagnostic methods that were used in that time period. So we come to the fluorescent microscopy mucous membrane of the stomach, which is the goal of this work.

-Stomach-wall consists of four layers: serous, muscular, and submucosal part. The mucous membrane (tunica mucosa) is clearly divided into two parts, esophageal part (pars proventricularis), one of the glandular part (pars pars glandularis still intestinalis), parts irregular, tortuous raised edge Margo plicatus or (Cuticular edge). The mucous membrane is further divided into three zones according to types of glands contained but there is no border between them. Cardiac mucosa extends in a narrow zone ruffled edge (Margo plicatus) but does not go to a big curve. It is yellowish gray in color and contain short tubular cardiac glands (cardiac gland area). On the part of the cardiac mucosa continues fundus mucosae, quite spacious, pinto and red, and reserves the right gastric glands (area fundus mucosae); these glands have two different kinds of cells. That part of the mucous membrane is thick and abundant blood vessels and the corresponding fundus of the stomach in humans and dogs. The remaining mucosa is thinner reddish-colored or yellowish in color and contain pyloric gland whose cells are biased and coincide with major holdings of cells (Sisson and Grossmann, 1962).


-Stomach-wall consists of a mucous membrane, submucosa, muscle layer and serosa. In species in which the change is made on the transition of the epithelium of the esophagus to the stomach where the entire inner surface is coated only glandular mucosa, the stomach is free or true stomach - ventriculus simplex (man, dog, rabbit, etc.). The mucosa of the stomach is composed of three layers: 1). lamina epithelialis; 2). Fur - lamina propria mucosae; 3). lamina muscularis mucosae. The epithelium formed recesses in glandular. According to the development characteristics of epithelial glands and mucous membranes distinguish cardia, fundus ventriculi and pylorus.

Fundus ventriculi - bottom of the mucous membranes of the stomach is made up of specific differentiated glandular epithelium that forms a branched recesses known as fundus gland - Gll. gastricae propria. These glands are provided as simple or branched tubular gland until the lamina muscularis mucosae. Are arranged in groups of three to seven nodes that flow into a common crypt. In each gland holdings of the superficial mucosal glandular cells, cervical mucous cells, the main - Pepsinogen, marginal - acidogenic and endocrine glandular cells. There are undifferentiated cells that play a role in the restoration of the epithelium.

The multi-chamber stomach is found in ruminants and birds. Stacked not glandular part consists of three cavities or extended parts - rumen and true glandular stomach. Rumen are covered with skin and mucous membranes are known by the following names: the rumen, reticulum, and omasum. Part of the stomach, which is lined with glandular mucosa is a true stomach and is known as rennet - abomasum (Pantic V, 1981).

- In the stomach are two completely different types of nodes, specific gastric glands and pyloric glands. Specific glands are all over the wall of the corpus and fundus of the stomach, and pyloric antrum are located in the part of the stomach. In addition, immediately below the cardia is something cardiac glands, which are almost identical with pyloric glands. Specific gastric glands secrete digestive juices, and pyloric and cardiac almost exclusively secrete mucus to protect the gastric mucosa. Typical specific gastric gland which is located in the fundus has three different types of cells: the side (mucoid) cells, which secrete mucus identical to that of pyloric gland; the main cells, which secrete digestive enzymes - especially pepsin - the edging strip and cells, which secrete hydrochloric acid and which lie behind the mucous cells and, more rarely, after the main cell.

The basic mechanism of secretion of hydrochloric acid. Outer cells (marginal) secrete electrolytic solution in addition to 7 mmol KCl containing 160 mmol per liter of hydrochloric acid. This acidic solution has a pH of about 0.8 - of which the sight that is very acidic. When such a pH, the concentration of hydrogen ions about four million times greater than in the arterial blood. In order to concentrate hydrogen ions in such a large scale, a great amount of energy. Hydrochloric acid is produced in the cells of the coating from the sodium chloride and carbonic acid ester according to this formula:



Accordingly, the blood that goes from active gastrointestinal mucous membrane contains a reduced concentration of sodium chloride, and the increased concentration of sodium, while at the same time going into the lumen of the stomach hydrochloric acid (Arthur C. Guyton, 1965).

-By cells that secrete mucus and lining the entire surface of the stomach, gastric mucosa there are two main types of tubular glands: oxyntic (gastric) glands and pyloric glands. Oxyntic glands (those which produce acid) secrete hydrochloric acid, pepsinogen, an internal factor and mucus. Pyloric glands secrete mainly serves to protect the pyloric mucosa of gastric acid. They also secrete the hormone gastrin. Oxyntic glands on the inside surface of the body and fundus of the stomach, which represents the top 80% of the stomach. Pyloric gland are located in the antrum part of the stomach, which account for 20% of the stomach.

Secretion of oxyntic (gastric) glands. A typical oxyntic gland consists of three types of cells: (1) mucosal cell door, which mainly secrete mucus; (2) the peptic (or main) cells, which secrete large amounts of Pepsinogen (3) of the parietal (or oxyntic) cells, which secrete hydrochloric acid and the internal factor.

Parietal cell (also called oxyntic cells) contain highly branched intracellular tubules. Hydrochloric acid is produced on tufting outcrops in these ducts, and then sinks to the secretory tubules end cells (Arthur C. Guyton and John E. Hall, 2008).

-Stomach is wrinkled - Ruga, these wrinkles are very pronounced in the area of the corpus and fundus of the stomach, and the only light indicated in the pyloric area. Simple prismatic epithelial cells that secrete mucus lining the entire stomach and are able to adapt to different pressures to which the mucosa subjected during the contraction of the stomach. In areas where there are peptic gland, the gastric mucosa showing shallow depressions, gastric cavity - foveols, where there are open gastric glands. These glands secrete mucus composed of a mixed hydrochloric acid, enzymes, and mucus. Between prismatic cells of mucosal epithelium and cells of real glands are the main cells that secrete mucus door slightly different composition than mucus secreting surface epithelia cells.

In all animals there are two major types of cells of gastric glands: (1) the main or peptic cells in the body increased which produce proteolytic enzymes, (2) the parietal (or oxyntic) cells, which secrete hydrochloric acid. Parietal cells are large cells that stained eosin bright red, and have a round, centrally set sail. They are most numerous in the upper third of the gland and rarely meet in the middle part mixed with peptic cells. The cytoplasm contains a large number of mitochondria and shows a fine web of canals.

The secretion of hydrochloric acid. Hydrochloric acid is located in the gastric juice of vertebrates. Studies electron microscope showed that there were changes in the structure of the parietal cells during stimulation of gastric secretion. The most striking change consists in the

emergence of a large number of intracellular tubules and increasing their surface due to the presence of a large number of small villi (microvilli) which line the ducts (Dukes Hugh H, 1970).

-Gastric Glands and secretions. The term gastric juice refers to the combination of substances secreted into the lumen of the stomach by gastric glands also termed gastric pits because of their Pitlik extension into the wall of the stomach, and epithelial cells of the stomach mucosa. Gastric juice contains water, hydrochloric acid, mucus, intrinsic factor, pepsinogen (an inactive form of pepsin, a proteolytic enzyme), and the enzyme rennin. The regulation of gastric juice secretion has three phases, cephalic gastric, and intestinal. Stimulation of gastric secretions during the cephalic phase is in response to the sight, smell or taste of food. These induce a neural response that increases parasympathetic (vagal nerve) stimulation to the stomach, and this stimulates gastric secretions. The gastric phase begins when food enters the stomach.

The presence of food, especially protein, stimulates the secretion of the hormones gastrin and histamine from cells in the gastric epithelium. Gastrin and histamine stimulate parietal cells in gastric glands that secrete hydrochloric acid. Acetylcholine (parasympathetic neurotransmitter) also stimulates parietal cells to secrete hydrochloric acid, but all three regulators (gastrin, histamine, and acetylcholine) must be present for the most efficient hydrochloric acid secretion. The histamine receptors on parietal cells (H₂ receptors) are different from those on cells involved in allergic reactions (H₁ receptors). The specific H₂ receptor antagonists provide a means to reduce acid secretion with few side effects. The antihistamines used for allergies do not bind to H₂ receptors and thus do not disturb digestion. The hormones cholecystokinin, gastric inhibitory peptide, secretin and inhibit hydrochloric acid secretion. These hormones are released from the duodenal epithelium in response to the presence of food in the duodenum. The release of these hormones that act to inhibit gastric function is part of the intestinal phase of gastric regulation. The pH of gastric juice and mammals can be 2 or less. The low pH is protective and that most foreign microbes and GESTEDE with food can not survive such an acidic environment. The low pH inhibits hydrochloric acid secretion to prevent it from becoming too acidic. Pepsinogen (an inactive form of the enzyme pepsin and a component of gastric juice) is activated by the low pH. By its proteolytic activity of pepsin can not activate pepsinogen. The low pH also promotes the activity of pepsin, because the most favorable pH range for its proteolytic activity is 1.3 to 5. Chief or peptic cells secrete pepsinogen to begin protein digestion is completed in the small intestine by other digestive enzymes.

A layer of mucus covers the epithelial lining of the stomach and protects the epithelium from the low pH of gastric fluids. This mucus is produced by cells in the gastric glands and is secreted from there onto the surface of the epithelium. Mucus secretion is stimulated by prostaglandins, which are also produced locally in the wall of the stomach. Non-steroidal anti-inflammatory drugs

(such as aspirin and phenylbutazone) inhibit the Synthesis of prostaglandins, and toxic doses of these agent are associated with gastric ulcers. It is presumed that a lack of mucus secretion contributes to the development of ulcers.

Rennin is an enzyme in the gastric juice in the abomasum of young ruminants. Its function is to coagulate milk and reduce its rate of passage through the gastrointestinal tract. Intrinsic factor and carrier protein for vitamin B₁₂, binds to the vitamin and the resultant complex passes through the tract to the ileum, which absorbs the B₁₂. (Rowen D. Frandson, Wilke W. Lee, Anna Dee Fails, 2009).

-Each Region of the mucosa contains glands with characteristic cell types. Within the parietal area, the glands contain parietal cells. These cells are clustered in the neck, or proximal area of the gland. Their function is to secrete hydrochloric acid (HCl). Distributed among the parietal cells in the neck of the gland is another type of cell, the neck mucous cells. These cells secrete mucous thin mucus less viscous than that of the surface mucous cells. The mucous neck cells, in addition to their edition secretory function, appear to be the progenitor cells for the gastric mucosa. They are the only cells of the stomach lining capable of division. As they divide, they either migrate down into the glands or up into the pits and onto the surface epithelium. As they migrate the mucous neck cells differentiate into any of several types of mature cells of the gastric glands and surface. In the base of the gastric glands is yet a third type of cell, the chief cells. These cells secrete pepsinogen, the precursor to the digestive enzyme pepsin.

The glands of the cardiac and pyloric mucosal regions resemble those of the parietal area in structure but contain different cell types. The cardiac glands secrete mucus only. Their mucus is alkaline and probably serves to protect the adjacent esophageal mucosa from the acid secretions of the stomach. The pyloric glands have noparietal cells but contain the gastrin - producing G cells. According to most reports, the pyloric glands to secrete pepsinogen. (James G. Cunningham and Bradley G. Klein, 2007).

-Ventriculus simplex. Wall simple stomach grade 4 Layer: mucous membranes (tunica mucosa), submucosa (tunica submucosa), muscle layer (tunica muscularis) and serous layer (tunica serosa).

Mucous membranes in all parts of the stomach consists of three lists: the epithelial sheet (lamina epithelial), furs (lamina propria mucosae) and muscular sheet mucous membranes (lamina muscularis mucosae).

Gastric glands are tubular úvrat'-crypt epithelial sheet mucous membranes that can reach up to mucous membranes of muscle list.

Cardiac glands (Gl. Cardiacae). These glands are located in the fur of the cardiac region of the stomach. These are short branched tubular epithelium of glands. Glands make mucous cells, which correspond histologically mucous cells and pyloric gland cervical mucus cells of fundic glands.

Fundus, the main gastric glands (Ch. Gastricae propria). Fundus glands are long tubular glands which are parallel to place. Usually a group of several glands opens into the

bottom of one foveols. These glands reach to the sheet of muscle membrane and are responsible for the secretion of gastric juice. Gastric glands consist of glandular body and distal narrowing of doors, which flows into the aforementioned foveole. Fundic gland build the following types of cells: a) Core (zymogen pepsinogen), b) and parietal (marginal, hloragogene), c) and mucosal (neck), d) Motherboard e) Enteroendocrine.

The main cells are small, irregularly prismatic, which lie in a single layer on a basal membrane. To the largest sekrets cell gastric glands, located deeper in the body glands. The free surface of cells carries short microville, and distal cytoplasmic granules. Pyloric gland (gl.pyloricae) accomodate in fur pyloric region of the stomach. They are short, tubular, branched and curled a foveols are deep-set. These nodes contain only a single cell type, that are mucous cells, similar mucous cells of fundic glands door.

The complex stomach of ruminants consists of four extended sections which are interconnected. Three compartments: rumen, reticulum and omasus make aftergaster-proventriculs, and the fourth section is rennet (glandular stomach-abomasus). Glandular stomach is true stomach, thickened glandular mucosa, and can be carried out from fundus and pyloric simple stomach. Histological structure of the glandular stomach is similar to the simple structure of stomach. Glands stomach has 4 layer: mucous membranes, submucosa, muscular layer and serous layer (Vesna Poleksic at all. 2003).

- Venticulus, Gaster is a wide, hollow organ that connects the esophagus and the small intestine and is the widest part of the alimentary canal. The inner surface of the stomach lining single-layer prismatic epithelium. Úvrat' epithelium formed glands, namely: cardiac-gl.cardiacae, fundusne-gl.gastricae and pyloric-gl.pyloricae.

Gl.cardiacae-cardiac gland, are circularly arranged at the place of transition of the esophagus into the stomach. They are simple tubular glands curled and consist of mucous cells. They are formed dipeptidase and esterases.

Gl.gastricae propria in stomach fundus are simple tubular glands and extend through the fur to muscular lamina. In each gland differs bottom, phone, neck and isthmus. They are the main pepsinogen, edge-acid production, door and other cells.

Heavy-Pepsinogen cells are the most numerous. They are in the bottom area of the body glands. The core of their roundish basal and lies.

The cervical cells are placed in the neck glands. Sails on them, basal and apical part of the cells of mucus, and is therefore called mucoïd or mucosal cells.

Pyloric-gl.pyloricae are curled, shorter than the glands of the cardia. Their glandular epithelium consists of cells that produce mucus (mucoïd cells), gastrin, etc., And between them are Pepsinogen, acid production and endocrine cells.

Ruminants have a multi-chamber stomach. Part of the stomach that is completely coated with cutaneous mucous membrane is separated into three separate cavities, of production of which is separated by a wall glandular

mucosa. These cavities are called: -rumen, reticulum and -omasus. Part with glandular mucosa of the stomach is called the true stomach or rennet-abomasus (Šijački N. at all. 1997).

-In glands lining of the stomach, there are three types of nodes: gl.cardiacae, gl.gastricae propria and gl.pyloricae.

Fundus the mucous membranes of the stomach pigs, horses and dogs is thicker than glandular mucous membranes in other regions of the stomach. It is darkly red, bumpy and educates the folds in the stomach. These folds extend in different directions. On fundus mucose perceive the recess (foveoles gastricae) and furrows that share this area of mucous membranes in the lower fields (area gastricae). Landscape holdings mucous membrane (pars fundic) in pigs stretches along the ventral part of the large curvature of the stomach. It lines the cranial and caudal wall of the stomach, but does not reach the small curvature of the stomach. Fundus mucous membranes in the stomach of the horse represents about 2/3 to 3/5 of glandular mucosal his stomach. Fundus of dog coats the mucous membranes in the left 2/3 of the wall of the stomach. The part fundus mucosa, which is closer to the left side of the stomach is lighter in color than the one that is closer to the pylorus. Pyloric the mucous membranes of the stomach lining pig stomach walls piloric work. Area pyloric mucous membrane of the stomach stretches right along the greater curvature to the pylorus, then with a small curvature of the stomach (Simic V, Z. Jankovic, 1997).

-Fluorescent Microscopy is used for studying the structural relationship between the protein and fat in cheese (King, 1958; Mulder et al. 1966; Shim - et al., 1982). Similar techniques have been used to explore the structure of the distribution and other ingredients such as salt crystals, from starter bacteria and mold on the surface of the cheeses prepared using a variety of methods of ripening.

Knowledge of the chemical and structural composition of dairy products is very important as it can help improve the production flow and / or product quality. Several analytical methods that are used to study chemical and structural aspects of dairy products. Fluorescence microscopy is one of the few that can provide information on both aspects at the same time, and for a short time. The ingredients of dairy products (proteins, fats, microorganisms Ltd.) May become visible through the interaction of a small amount of the samples with specific colors or with fluorescent reagents (Shyi, 1985).

-Gastroscopy is perpetrated fiberoptic ezofago-gastro-duodenoskop (Olympus, GIF-Q145), which is equipped with a pair of pliers for taking biopsy samples. Endoscopic findings were described with data on the site changes, the size and appearance and are marked with the following terms: hyperemia, erosion, injuries and scar infiltrate.

HISTOLOGY-resecting and bioptic material fixed in 10%, or a standard 4% neutral-buffered formalin, embedded in paraffin, and fit to the cutout into slices of a thickness of 3 to 4 mikrona. Slashes were routinely stained Hemalaun-eosin. The presence and quantity of H. pylori

was determined semi quantitatively in sections stained modified method - 2% Giemsa (89).

The presence and density of the infiltrate of lymphocytes and plasma cells was assessed and graded Wotherspoon-in according to (40).

-Immunostaining were performed immunohistochemical staining with primary antibody (DAKO, Denmark): CD3 (A 0452), CD20 (M0755), CD5 (M7194), CD23 (V1617) and CD10 (Novocastra Lab, NCL CD10-270) according to instructions manufacturer, using the conventional method or device for automated immunohistochemical staining of "Techma Horizon" (DAKO, Denmark). Immunohistochemical staining was performed for BCL10 concentrated with anti-BCL-10 monoklonalnimantitelom, clone 151 (ZYMED®Laboratories Inc. USA) at a dilution of 1:50.

After dewaxing, the unmasking of antigen cells in histological sections we have done in the cooking pot under pressure in 0.01 M citrate buffer pH 6.00. Secondary and tertiary antibody (streptavidin-peroxidase) was used in the set "LSAB + System, HRP" (K 0609, DAKO, Denmark). Preparations were contrasted with hematoxylin, a maximum of 1 min. As a positive control we used the tonsil tissue.

Fluorescence in situ hybridization (FISH) on paraffin sections FISH (Fluorescent in situ hybridization) is a cytogenetic method in which fluorescence labeled nucleic test investigating the desired nucleic acid sequence within the chromosome. After purifying the protein from the cells and denaturation of deoxyribonucleic acid (DNA) leads to labeled test and hybridization of a DNA sequence studied. The color used is labeled test absorbs one, and missed the other end of the spectrum, however, specific DNA sequences on chromosomes under a microscope can be seen as clear signs of red / green / yellow. To make the picture clearer under a microscope for stronger contrast is used DAPI staining of nuclei-operation (4.6 -diamidino-2-phenyl-indole). Thus can be seen sharply limited core within which the color signal which is dependent on the design of a single test.

In our study we used the CEP (Chromosome Enumeration test) DNA FISH Test for the detection of chromosome centromeres third producer Vysis Inc. USA (VYS CEP3 PRBS 31-130003. (Gašparov S, 2004).

-The gastric secretion of proteolytic enzymes, hydrochloric acid and mucus has been associated with characteristic types of cells and glands in the gastric mucosa; these cells and endocrine cells present in the glandular gastric mucosa are not distributed uniformly throughout the stomach. Thus, in the glandular stomach unilocular (terminology, Langer, 1984) such as that of man, three main areas of the mucosa are identified: cardiac, fundic or oxyntic and pyloric (Ito, 1968). The exocrine secretions of the cardiac and pyloric glands are alkaline with a high content of mucus, those of the oxyntic area may contain acid, enzyme and mucin. The areas differ in extent and the unilocular stomach, with the cardiac gland area being relatively narrow in the stomachs of cat, dog and human. In animals in which a multilocular stomach has developed, these glandular areas are most

commonly located in the stomach caudally lying between sometimes capacious non-glandular gastric compartments and the duodenum. The stomach of the pig presents, in some respects, a form intermediate between the uni- and multi-ocular types of stomach because it has a small gastric diverticulum and stratified epithelium at the cardia; There is an extensive cardiac zone with glandular epithelium extending into the diverticulum (Sloss, 1954), and oxyntic discrete and pyloric gland areas (P Langer, 1984).

III. MATERIAL AND METHODS

In one slaughterhouse near Leskovac, at the slaughter line we have, after examination of the digestive tract, stomach took samples from 15 cattle and 15 pigs. The animals were the same age categories, belonged to the category of fattening animals. Pigs were about 6 months of age and average body weight of about 100 kg. Bovine animals were between the ages of 5-7 months with a weight of between 400 and 500 kg. Take samples of gastric fundus pigs and cattle abomasus placed in jars with the already prepared solution formalins. Treatment samples and fluorescence microscopy were carried out in the laboratories of the Institute of Forensic Medicine at the University of Nis. During the preparation of histological preparations we made sure to respect the sequence of events in the development of products, which includes the following: 1. dissection, 2. taking of tissue or organs, 3. grinding, 4 fixation (formalin, alcohol, Bouin, etc.) 5. dehydration (series of alcohol, xylene), 6 paraffination (in liquid paraffin in a thermostat), 7. molding using paraffin, 8. Cutting mold microtome (4-6 microns), 9. nanošenje paraffin sections on the carrier object (object glass), 10 deparaffining 11 Introduction downward range of alcohol to water, 12 dyeing, 13 dehydration in ascending series of alcohols and xylene, 14 mount using Canada balsam and covering flakes. The slides were stained with hematoxylin-eosin and examined by passing the light (TL) and under indirect light fluorescence (ILF), using a wavelength of 556 nm with a magnification of 10 times (Nitovski A, 2009).

For fluorescence microscopy, we used fluorescence microscope Zeiss Axiophot.

Phase-contrast microscope has a special lens and a diaphragm, which allow to create a much greater contrast between the object and the environment. This microscope allows the observation of the living, unpainted objects. A fluorescence microscope is used for visualization of objects that have the ability to give the light of a certain color that fluoresce when illuminated by ultraviolet light. If the subject has no possibility of fluorescence, treated with the appropriate fluorescent colors- fluorohroms. This type of microscope is widely used in the identification of microorganism, which uses antibodies labeled with fluorescent dyes, which bind to the desired antigen, ie. microorganisms.

Fluorescent staining allow detection of lower concentrations (1×10^4 cells / ml). Examples include acridine orange (bacteria and fungi), auramine-rhodamine

and auramine O (mycobacteria) and kalkofluor (fluorochrome) white (to fungi, especially dermatophytes become fluorescent under ultraviolet light microscope).

Connecting a fluorescent dye to the antibody to agents (direct or indirect immunofluorescence) theoretically should increase the sensitivity and specificity. However, these tests is difficult to read and interpret a few of them available in the market and in daily use (eg, direct immunofluorescence test to pneumonia and legionella).

American scientists Erik Becig and William Merner and German Stefan Hel are the Nobel Prize for chemistry, to develop new methods that allow the microscope to "see" better than ever.

The basis of the work of Stefan Hella fluorescence microscope for which it obtained the Nobel award. It has been standard for decades in the study of cells. In normal light microscope anything less than 200 nanometers was quite unclear until Stefan Hell was not have thought of an ingenious idea: if you are already fluorescent molecules can "activate" why could not the "deactivate"? "If we take, for example, a blue laser to activate them. The blue laser is a high-energy laser, with the energy of the yellow laser. To deactivate the molecule to the blue laser "we put on" yellow light. In this way, only a few remain visible rays of light in the middle of the molecule in such a way that it fluorescent area can theoretically seem as sharp as much as anyone needs. That is what is in this new microscope. "What is the area less, the higher the resolution. Now you can peek in the interior of the cell size of just 20 nanometers. It could, however, and the electron microscope and sounding microscope, but the cell is then dead. A fluorescence microscope is the only one can be seen live cells. A can be seen, for example, how it is influenced by drugs or as a substance from one nerve cell to another are delivered.

IV. RESULTS AND DISCUSSION

Samples of gastric mucosa of pigs and cattle have observed on a fluorescent microscope, noted the existence of all types of cells in the gastric glands situated foveole of stomach. We observed the existence kardiak and pilorus glands, but are the biggest attention to the glands and cells of the gastric fundus. After completing the observation we made a record of certain products, and the resulting images have enabled us to compare individual cell types as constituents of gastric glands, as well as to compare the gland and its cells in pigs and cattle. These results were compared with the results that we have found review of the literature and papers related to this field.

Thus, for example, Carlos Rubio and his associates on a fluorescent microscope to analyze samples of gastric mucosa 35 ape baboon. They are like and we use hematoxylin eosin staining (H & E). The thickness of the parietal cell population was assessed at 10 × magnification. The authors have obtained the following results: H & E stained all mucosal cells: fovelar, parietal and chief cells. When the same sections were analyzed with an FLM, only parietal cells were auto-fluorescent, whereas fovelar and chief cells remained non-fluorescent.

Parietal cells formed a distinct, continuous band autofluorescent. The ratio of the auto-fluorescent parietal cell band / total mucosa ranged between 0:20 and 0:30. We are conclusion that the gastric parietal cells became auto-fluorescent when H & E-stained sections from baboon stomachs were observed with an FLM. Eosin stain was the responsible for this optical phenomenon.

Similar results we have received since we used hematoxylin and eosin for staining and stomachs of baboons, pigs and cattle belonging of mammals. In this sense, we did not expect a big difference in the distribution, size and location of individual glandular cells in the gastric fundus in baboons, pigs and cattle .

And 1987, Gherardi et al. tested four different stains to study parietal cells in the rat stomach: (i) a modification of the H & E method proposed by Drysdale and Marks, (II) hematoxylin-eosin-saffron fluorochrome stain, (III) hematoxylin-azophloxin-saffronfluorochrome stain and (IV) May-Grunwald-Giemsa stain on thin sections from plasticembeddedspecimens. According to Gherardi et al., Plastic-embedded specimensstained with the May-Grunwald-Giemsa stain provided the best results for the visualization of parietal cells in rat stomachs. It should be stressed that by using this complex, costly and time-consuming method, only very small areas of gastric mucosa (1 to 2 mm) can be analyzed.

More than one-third of the stomach of pigs and cattle rennet is covered fundusnom When gastric mucous cells stained with hematoxylin and eosin (H & E), we have identified several types of cells in the mucosa of fundus; the upper one-fifth of the surface containing mucous epithelial cells in cervical foveole. Two to three-fifths, the cladding (oksintic) cells, and the rest of the other part, represent dark- main cell.

Various methods have been so far applied in the study of the parietal cells, such as isolation and separation of enriched fractions of the variable in the parietal cells of the mucous membranes in the samples and immunochemical analysis. These methods, however, are cumbersome, lengthy and not for use in the diagnosis of veterinary histology and pathology.

Preparations were taken with the camera, which is an integral part of the microscope, and some shots, we present it as an integral part of our work. The footage clearly shows gastric gland cells that build them a) Core (zymogen pepsinogen), b) and parietal (marginal, hloragogene), c) and mucosal (neck), d) Motherboard e) Enteroendocrine.

V. CONCLUSION

1. Our task was to carry out a suitable method of microscopic examination and analyzing certain parts of the gastric mucosa of cattle and pigs, with particular emphasis on the gastric fundus mucosa of pigs and cattle abomasusa. We opted for fluorescence microscopy has enabled us to contrast coloring of certain parts of cells observe all cells glandular cells of the gastric mucosa, residing in mucosal foveoles.

2. We are notice that only parietal cells were auto-fluorescent, where around foveols chief cells remained non-fluorescent. Parietal cells formed a distinct, continuous band autofluorescent.
3. This method allows many other tests such as comparative test number, distribution and size of the glandular cells foveols holdings of certain types of domestic animals and compared these cells with cells of the stomach of man.
4. More than one-third of the stomach of pigs and cattle rennet is covered fundus mucosae. When gastric mucous cells stained with hematoxylin and eosin (H & E), we have identified several types of cells in the mucosa of fundus: the upper one-fifth of the surface containing mucous epithelial cells in cervical foveols. Two to three-fifths, the cladding (oksintic) cells, and the rest of the other part, represent darks- main cell.

REFERENCES

- [1] Septimus Sisson, James Daniel Grossman (1962): Textbook of Anatomy of Domestic Animals, Ohio State University, Columbus, Ohio, USA, p.475-480.
- [2] Pantic Vladimir (1981): Textbook of Histology II, University in Belgrade, Belgrade, p. 276-230.
- [3] Guyton Arthur C. (1961): Textbook of Medical Physiology, Philadelphia and London 1961, Translate Medical Book, Belgrade-Zagreb, 1965, p.798.
- [4] Arthur C. Guyton, John E. Hall (2008): Textbook of Medical Physiology, Translate Modern Administration, Belgrade, 2008, p. 771st
- [5] Dukes Hugh H. Melvin J. Swenson (1970): The Physiology of Domestic Animals, by HH Dukes, Cornell University Press, Itaca, Eight Edition, 1970, Translate Light, Sarajevo, 1975, p.367.
- [6] Rowen D. Frandson, Wilke W. Lee, Anna Dee Fails (2009): Anatomy and Physiology of Farm Animals, Wiley-Blackwell, 2009, p.345-346.
- [7] James G. Cunningham and Bradley G. Klein (2007): Textbook of Veterinary Physiology, Fourth Edition, Saunders Elsevier, p.300-302.
- [8] Vesna Poleksić, Jelena Bogojevic, Zoran Markovic and Zorka Dulic Stojanovic (2003): Textbook of Zoology, University of Belgrade, Agriculture faculty Belgrade, 2003, p.236-237.
- [9] Šijački N, apple Olivera-Pantic Pantic V. (1997): Textbook of Morphology of Domestic Animals, Science, Belgrade, Fifth Edition, 1997, p.257-259.
- [10] Simić V, Jankovic women. (1997): Textbook of Anatomy of Domestic Animals Mamals, Splanhnology, University in Belgrade, Veterinary Faculty, Belgrade, 1997, p.126-133.
- [11] SH Yiu (1987): Application of Fluorescence Microscopy and Dairy Science Dairy 38 (7) 171-178, Food Research Centre, Research Branch, Agriculture Canada, Ottawa, Ontario, Canada KIA OC6- Review, in 1987.
- [12] Gašparov, Slavko (2004): Trisomy 3 oncoprotein BCL 10 and MALT of gaster by infection with Helicobacter pylori, Doctors dissertation, University in Zagreb, Medical School Repository , 2004 <http://medlib.mef.hr/346>
- [13] Peter Langer (1984): Comparative Anatomy of the Stomach in Mammalian herbivores, the Institut für Anatomie und Cytobiologie, Justus-Liebig-Universitat Giessen, Aulweg 123, D-6300 Giessen, FRG Quarterly Journal of Experimental Physiology (1984), 69, 615-625 Printed in Great Britain.
- [14] A Nitovski, Bisa Radovic, Dragan Grčak, Valentine Milanovic, Milenkovic M, Grčak M. (2015): Influence of modern biochemical and biophysical test method to distinguish the anatomical, histological and physiological characteristics of the gastric mucosa, Research People and actual Tasks on Multidisciplinary Sciences Proceedings, Lozenets, Bulgaria, 2015.

- [15] Nitovski A, (2009): Practical exercises for the subject of this anatomy of domestic animals, the University of Kosovska Mitrovica, Faculty of Agriculture, 2009, p.10-12.

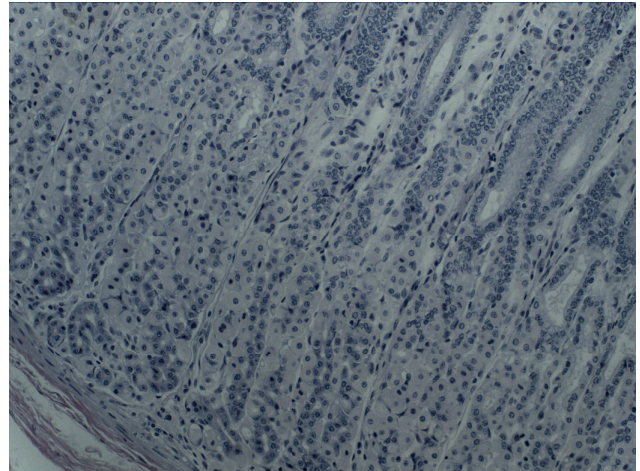


Fig.1. Fundus of cattle UV-10.

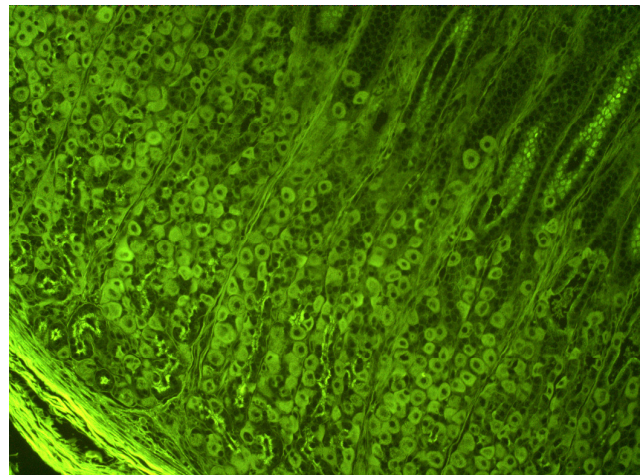


Fig.2. Fundus of cattle IF 10.

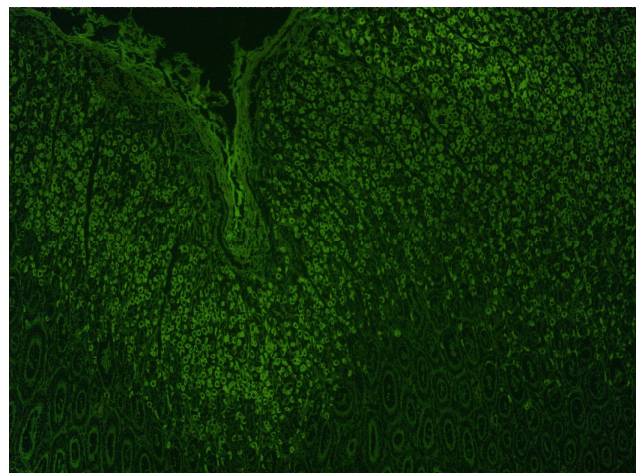


Fig.3. Fundus of cattle UV 100

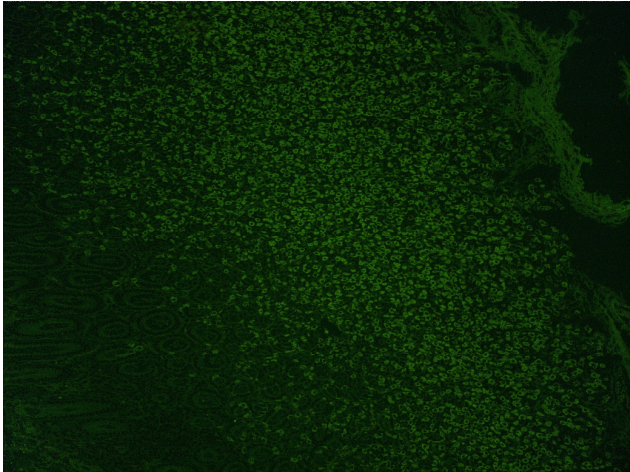


Fig.4. Fundus of cattle UV 100

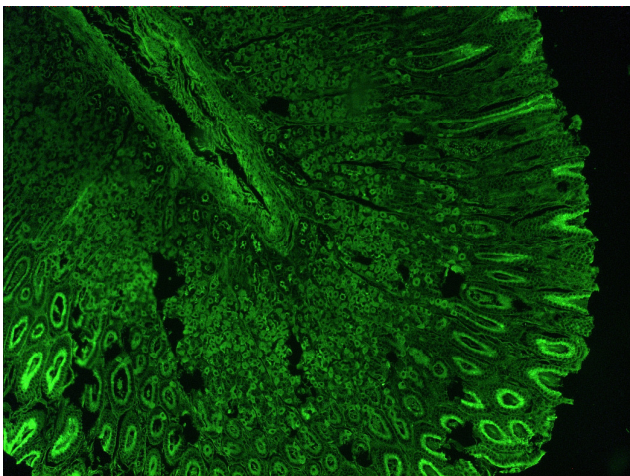


Fig.5. Fundus of cattle UV 100

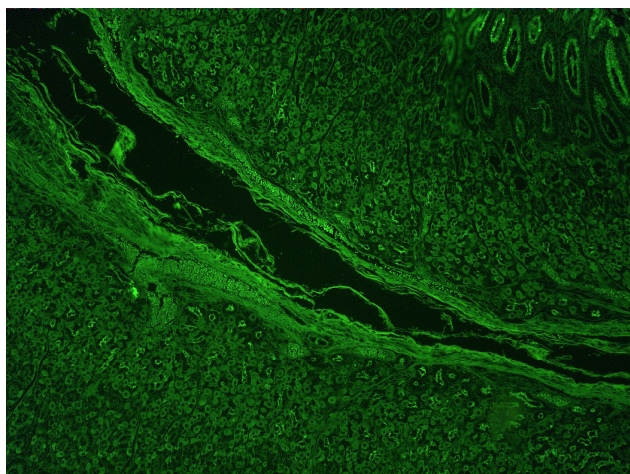


Fig.6. Fundus of cattle UV 100.